

In Vivo Intra-articular Negative Pressure Wound Therapy Effect on Cartilage in a Goat Model

Maj Kenneth Bode, MD,¹ Maj Charles Haggerty, MD,¹ Lt Col J. T. Tokish, MD,² and Lt Col Warren Kadrmas, MD¹

This prospective, randomized, blinded pilot study determined if a difference was present in the histology and apoptotic rate of articular cartilage after application of a negative pressure wound therapy (NPWT) device to an uninjured joint surface compared to a control side using Capra hircus goats. The goats were euthanized at 3 or 7 days after surgery. The en bloc joint resection was divided into medial (direct sponge contact) and lateral compartments (no sponge contact; indirect NPWT). In the necropsied cartilage and menisci, there were no gross or histologic/morphometric differences identified by a blinded veterinary pathologist. The percentages of apoptotic and necrotic chondrocytes based on flow cytometry were not statistically different. This study demonstrated that there were no observable deleterious effects to uninjured cartilage from direct or indirect intra-articular NPWT placement. These data suggest that NPWT may be placed safely in an intra-articular position for up to 7 days. Further studies in humans are warranted. (Journal of Surgical Orthopaedic Advances 20(1):44–49, 2011)

Key words: animal, cartilage, intra-articular, knee, negative pressure wound therapy

Negative pressure wound therapy (NPWT) has become a common treatment option for a variety of acute and chronic wounds: pressure ulcers, diabetic wounds, partial-thickness burns, trauma wounds, flaps, and grafts (1, 2). These systems deliver negative or subatmospheric pressure therapy. Multiple mechanisms of action, such as macro- and microstrain, help promote wound healing. Macrostrain is the visible alteration that occurs when negative pressure contracts the foam, drawing wound edges together and removing exudate and infectious materials (3, 4). Microstrain occurs at the cellular level leading to cell stretch, which reduces edema, promotes perfusion and granulation, and influences tissue formation through cell mitosis, proliferation, and fibroblast migration. The wound sponge is an open-cell foam surface dressing that assists tissue granulation and is sealed with

an adhesive drape that allows the subatmospheric pressure at the wound site. The body of clinical evidence for NPWT contains more than 300 peer-reviewed articles. FDA precautions include not placing the foam dressings directly in contact with exposed blood vessels, anastomotic sites, organs, or nerves. The indications and effect on cartilage with placement of intra-articular NPWT are currently unknown. This lack of knowledge does not assure surgeons that these devices can be placed within joints.

Adult articular cartilage is devoid of normal vascular routes of nutrition for chondrocytes. Two routes of nutrition have been theorized. The first and most prevalent theory is that the synovial fluid provides nutrients through simple diffusion and hydrodynamic pressure. The second theory is that the nutrients diffuse through the subchondral bone and vascular buds that penetrate the calcified cartilage layer (5). There may be deleterious effects of exposing articular cartilage to air (6, 7). The supposition is that exposure to air deprives the joint of its source of nutrition, the synovial fluid (8). NPWT has the same effect by actively removing synovial fluid from the joint through production of negative pressure. There is also potential direct mechanical damage from the sponge to the surrounding structures. One article in the German literature found hypertrophic tissue on a femoral condyle exposed to a NPWT device (9). The purpose of this pilot study was to determine if there would be a difference in the histology and apoptotic rate of articular cartilage after application of NPWT. It was hypothesized that there would be a significant detrimental effect present.

From ¹Wilford Hall Medical Center, Lackland AFB, TX; ²United States Air Force Academy, Colorado Springs, CO. Address correspondence to: Maj Kenneth Bode, 2200 Bergquist Drive, Suite 1, SGOYO, Orthopaedics, Lackland AFB, TX 78236; e-mail: Kenneth.bode@us.af.mil.

KCI donated the animal wound vacuum system, harness/sourcil, and wound vacuum supplies. These were returned to KCI at the end of the study. No financial compensation was provided by KCI. The USAF provided all other animals, facilities/personnel, and funds. None of the authors have any professional and/or financial affiliations that may be perceived to have biased this study.

Received for publication November 8, 2010; accepted for publication November 10, 2010.

For information on prices and availability of reprints call 410-494-4994 X232.
1548-825X/11/2001-0044\$22.00/0

Methods

This was a prospective, randomized, blinded study that observed the histologic differences of cartilage between 10 *Capra hircus* goat knee joints that had an intra-articular NPWT placement and appropriate control. Half of the goats had the NPWT treatment for 3 days and the other half had 7 days of treatment. These timeline points were chosen based on typical times required for primary closure of wounds.

Before surgical incision, Ancef (25 mg/kg IV) was given to each goat. A medial parapatellar knee arthrotomy was placed on the bilateral hind legs of each goat: one as control and one as study (using the goat as its own control). Hemostasis was ensured and followed by irrigation with 60 cc of normal saline. The articular cartilage was examined for gross abnormalities before proceeding with NPWT placement or primary closure.

A randomized side then had KCI's Therapeutic Regulated Accurate Care (T.R.A.C.) pad (Kinetic Concepts, Inc., San Antonio, TX) (aka NPWT sponge) placed within the medial compartment of the knee in contact with both the femoral/tibial chondral surfaces and the medial meniscus. The everted edges of the capsule were sutured into the sponge to ensure that the NPWT remained intra-articular and in contact with the sponge and occlusive drapes were then applied after a circumferential benzoin tincture was applied. Ioban was also utilized at the periphery of the drapes to ensure that a seal was maintained. KCI's wound vacuum-assisted closure (V.A.C.) device was used with settings of 125 mm Hg continuous suction. An average of 40 and 70 cc of synovial fluid accumulated in the NPWT reservoir over the 3- and 7-day periods.

The control side was primarily closed in layers with 2-0 vicryl and 3-0 nylon running horizontal mattress. The goats then had a specialized sourcil harness placed to ensure the safety of the apparatus and tubing. This swivel mechanism within a hinge apparatus gave the goats full range of motion within the confines of the pen without threat to the NPWT. The metal sheath and Elizabethan collar ensured protection of the plastic tubing from the goats.

The goats were then euthanized at 3 versus 7 days after surgery; both aerobic and anaerobic cultures were taken (10, 11). En bloc joint resections of both joints were accomplished and fixed in 10% neutral buffered formalin (NBF). The en bloc resections of the NPWT joints were also divided into medial (direct sponge contact) and lateral compartments (no sponge contact; indirect NPWT). Following fixation, the joint was separated into trochlear and condylar regions and then sectioned. The menisci were also sectioned. The cartilage sections were placed in cassettes for decalcification and underwent

routine processing for hematoxylin and eosin (H&E) and safranin O staining. Histologic morphologic analysis was accomplished through H&E staining. Safranin O staining afforded histochemical evaluation for proteoglycan depletion, distribution, and accumulation and structural changes, which can correlate the severity of the cartilage insult. This also allowed for spatial localization relative to the articular surface to determine if cells closer to the NPWT were affected.

Cartilage from each joint section was prepared in Hank's buffered salt solution (HBSS, Sigma Chemical Co.) at 37°C for 3 hours with mild shaking (75 rpm), and a single cell suspension was obtained. Samples were rinsed with HBSS to remove collagenase and then separated into two fractions. The first sample was processed and stained for annexin V following the manufacturer's instructions using the BD Pharmingen Kit; the second sample was processed and stained for caspase 3, following the manufacturer's instructions from Cell Signaling Technologies. Both sets of samples were run on the BD FACSCalibur flow cytometer, and more than 10,000 events were collected and analyzed using CellQuest Pro software (12, 13).

When measured over time, annexin V and 7-amino-actinomycin D (7-AAD) can be used to monitor the progression of apoptosis: from cell viability, to early-stage apoptosis (annexin V only), and finally to late-stage apoptosis and cell death (annexin V and 7-AAD). One of the earliest indications of apoptosis is the translocation of the membrane phospholipid phosphatidylserine (PS) from the inner to the outer leaflet of the plasma membrane. Once exposed to the extracellular environment, binding sites on PS become available for annexin V, a 35- to 36-kDa, Ca²⁺-dependent, phospholipid-binding protein with a high affinity for PS. This is used in conjunction with vital dyes such as 7-AAD, which bind to nucleic acids, but can only penetrate the plasma membrane when membrane integrity is breached, indicative of necrosis. Another set of mediators implicated in apoptosis belong to the aspartate-specific cysteinyl proteases or caspases and were used to substantiate the annexin V data (14).

Statistics

Data from the flow cytometry analysis was examined using both parametric and nonparametric methods. There were two sets of groups for comparison: NPWT versus control hind limbs of each animal, and within the NPWT group, direct versus indirect (no sponge contact) placement. Student *t*-tests were used to compare the NPWT versus control hind limbs, and paired *t*-tests were used to compare direct versus indirect placement of the NPWT.

Results

Upon necropsy, gross anatomic review by a blinded veterinary pathologist indicated no perceived differences or gross lesions visible within each knee joint. The cartilage color, consistency, and contour did not differ between the NPWT and control groups. There was no observed difference between the direct application of the NPWT sponge (medial joint) versus the indirect effect of the NPWT (lateral joint). There was hyperemic, hypertrophic synovium present in the NPWT joints. The significance of this finding is unknown, but could represent anabolic versus catabolic mediators. Microbiology cultures showed no significant bacteria present within any of the samples, which if present would skew the results (10, 11).

Upon histopathology review, there were no significant histologic lesions observed on the trochlear or condylar articular cartilage or the subchondral bone (Fig. 1). The proteoglycan component of the articular cartilage was evaluated with safranin O stain. When comparing the different treatment groups, there were no appreciable differences in the safranin O staining in the examined sections (Fig. 2). The menisci were also examined through H&E staining. These sections also showed no deleterious effect from the NPWT with comparison between direct sponge contact and control. The synovial sections adjacent to the articular cartilage did show hyperemia and hyperplasia both grossly and histopathologically.

Statistical analysis of the flow cytometry echoed the finding of no difference between NPWT versus control. Figures 3 and 4 graphically illustrate the lack of difference between groups. The early apoptotic (AV+), late apoptotic (AV+/7-AAD), necrotic (7-AAD), and caspase 3 results were tabulated and statistical analysis was performed. Based on the Student *t*-test, there were no statistically significant findings between any of the groups: NPWT versus control, and within the NPWT group, direct versus indirect placement. These results were confirmed using Mann-Whitney nonparametric methods. The sample size of five per group was determined assuming that there would be large differences (more than 1 SD) between the groups if the NPWT had any effect on the articular chondrocytes. A post hoc power analysis revealed that the study had 80% power to detect a 2 SD difference between groups, and differences of this magnitude were not observed. These findings are in correlation with the histochemical analysis, since there should be large percentage differences between apoptosis and necrosis rather than small ones if a detrimental effect of the NPWT was truly present.

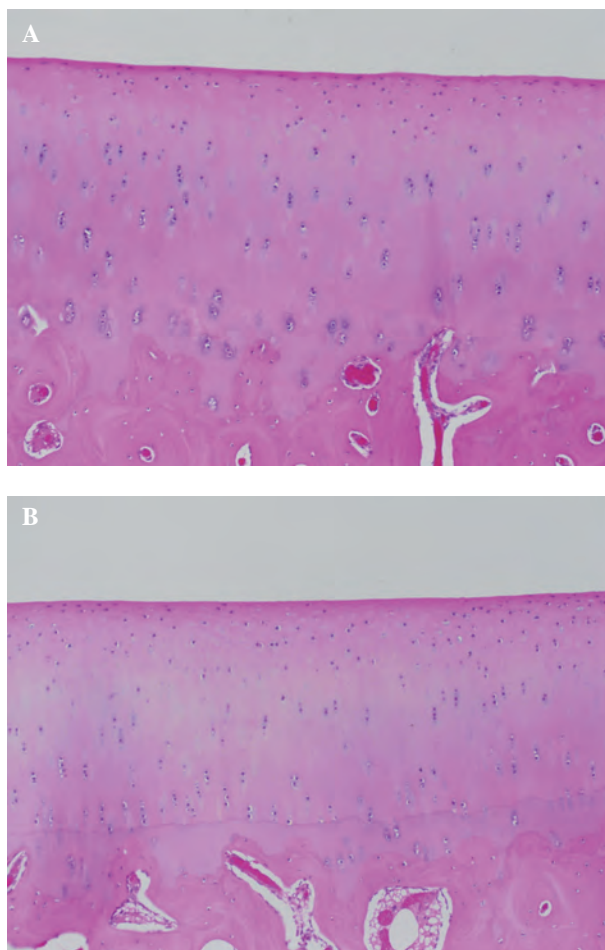


FIGURE 1 Day 7 cartilage H&E sections illustrating no morphologic differences between control (A) versus NPWT direct application (B). Tidemark differences secondary to processing and image quality.

Discussion

The purpose of this prospective, randomized, blinded pilot study was to determine whether a difference was present in the histology and apoptotic rate of articular cartilage after application of an NPWT device to an uninjured joint surface compared to a control side. Many surgeons are using NPWT devices for soft tissue repair. Occasionally, there is a need to place NPWT devices near or in contact with the joint surface, especially after trauma. This would place negative pressure on the joint and remove synovial fluid, presumed to supply nutrition to the joint cartilage. There is also a possible direct mechanical irritation to the surrounding structures. There are no published objective clinical trials addressing NPWT use within a joint. This study aimed to examine the direct and indirect effect of a NPWT in a nontraumatized joint. The normal biology and ultrastructure of the articular cartilage has been previously described and was used as comparison and benchmark for our standards (15).

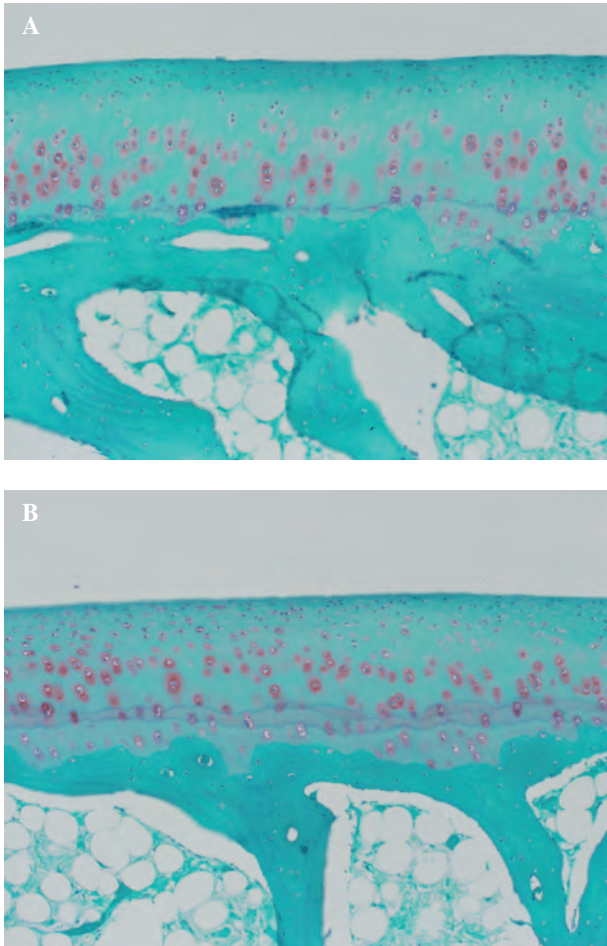


FIGURE 2 Illustrative section of Day 7 cartilage stained with safranin O. (A) Control for staining comparison. (B) Direct NPWT application. The amount of orange stain surrounding the chondrocytes indicates similar proteoglycan production, distribution, and accumulation without structural changes or difference in spatial localization compared to articular surface.

Upon histopathology review, there were no significant histologic lesions observed on the trochlear or condylar articular cartilage or the subchondral bone. The proteoglycan component of the articular cartilage, Aggrecan, was evaluated with safranin O stain, which stains proteoglycan in cartilage as bright orange. Without the chondrocyte production of these aggregating proteoglycans, the matrix's collagen metabolism is not impeded and the matrix undergoes mechanical failure and deterioration (16). The cartilage's ability to resist compressive loads through the proteoglycans and the tensile strength through the collagen are also diminished. When comparing the different treatment groups, there were no appreciable differences in the safranin O staining in the examined sections.

The results indicate that there were no differences in control versus therapy groups for either 3 or 7 days of

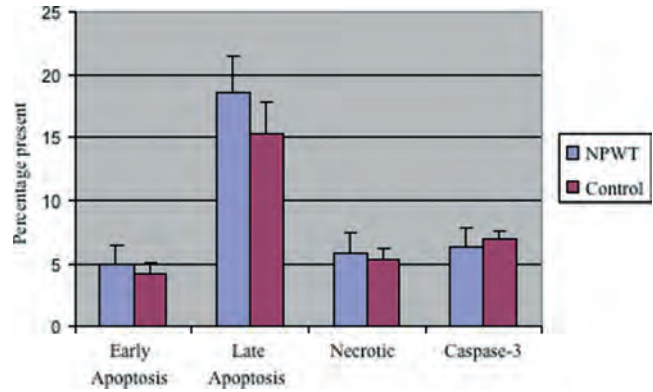


FIGURE 3 NPWT versus control effect based on caspase 3 and annexin V. The amounts of early, late, and necrotic chondrocytes were not statistically different within 1 SEM comparing NPWT treatment versus control. The caspase 3 analysis confirmed these findings.

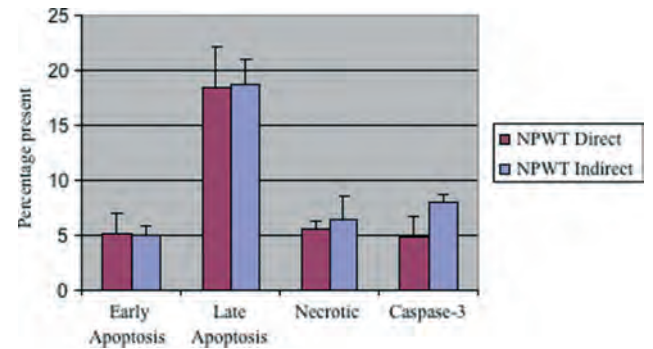


FIGURE 4 Direct versus indirect effect of NPWT based on caspase 3 and annexin V analysis. The direct effect of the NPWT sponge application onto the cartilage revealed no statistical difference within 1 SEM.

treatment. The possible application of NPWT is useful when large amounts of soft tissue destruction are present in a periarticular pattern. Time points of 3 and 7 days were used because 3 to 7 days of NPWT typically allows for flap coverage of the area. Further studies are required to determine if long-term use greater than 7 days is harmful. Also the long-term consequences of a brief period of NPWT are unknown. This study used single time points of evaluation, and there was an assumption that no chronic effect would occur in the cartilage if there was no difference in this early period. The effect of NPWT on traumatized chondrocytes is still unknown and this is an inherent weakness in this pilot study. This study did reaffirm the effect of an arthrotomy on cartilage with over 15% of chondrocytes having late necrosis; this effect has been shown to be transient and reversible within 6 weeks (6, 7).

Conflicting studies for the routes of chondrocyte nutrition exist. The early studies stated that the calcified zone of

cartilage constituted an impermeable barrier to the transport of material and most believed that nutrients reached cartilage only through the articular surface (17, 18). Some researchers considered that nutrition of cartilage occurred through both routes (19), while others felt that only growing cartilage derived a significant part of its nutrition from the underlying bone (20). Most of these early studies were accomplished in the 1950s, and the philosophy of an impenetrable barrier has been perpetuated.

Recent studies have shown that this theory of an impenetrable barrier is potentially false. The initial studies used permeability of solute through the articular surface as their method, disregarding the anterograde mode, or they used sections of cartilage that did not have vascular buds that penetrate. Studies have demonstrated that 5% of the deep aspect of articular cartilage is in direct contact with the articular vascular plexus and these channels invade the uncalcified layer (21–24). In comparison to another area of the body, the cartilaginous end plate within the spine has been accepted as playing an important role in the nutrition of the intervertebral disc. This cartilaginous area has similar histology to articular cartilage with a calcified cartilage area present, yet diffusion through vascular buds is an accepted method of nutrient transport (25, 26). The blood flow to the subchondral and cortical end plate is 3 to 10 times higher than in cancellous bone and this perfusion rate accounts for at least 50% of articular cartilage's nutrient requirement (27). Another correlative finding is that there is complete necrosis of articular osteochondral fragments, which, bathed in synovial fluid as a nutritional source, should maintain some chondrocyte viability.

There are a few theories for the continued nutrition of the chondrocytes within this study. First, the synovial fluid could continue to give nutrition to the cartilage through the hypertrophied synovium. The pressure required to completely remove the synovial fluid from the treatment area is unknown, and it is possible that the pressure of 125 mm Hg of continuous suction was not a high enough setting. The area in direct contact with the sponge may also receive nutrition from the surrounding cartilage through elastohydrodynamic lubrication. The second theory is the potential chondrocyte nutrition from the subchondral bone; this source should not be affected by this treatment. This is based on the assumptions that chondrocytes should not be able to maintain their morphometric parameters and production of glycosaminoglycans with decreased synovial fluid nutrition and that a certain percentage of nutrition comes from the subchondral bone. The debate over how much cartilage nutrition is received from each route continues, with the appreciation that the almost absolute barrier to diffusion of nutrients between articular cartilage and subchondral bone does not exist (28). Based on this study, it is unknown which of these routes had a role in cartilage nutrition.

The aim of this study was to examine whether intra-articular NPWT is harmful to uninjured cartilage, not its efficacy. Further studies are required to investigate whether NPWT is beneficial to intra-articular or periarticular pathology. There may be future studies to examine the use of NPWT in osteochondral lesions, especially since vascularization of subchondral bone is decreased with age and this area assists in repair of cartilage (28).

This pilot study demonstrated that there were no observable deleterious effects to uninjured cartilage from direct or indirect intra-articular NPWT placement compared to each other and to contralateral control. These data suggest that NPWT may be placed safely in an intra-articular position for up to 7 days. Surgeons faced with periarticular trauma wounds could possibly place NPWT in an intra-articular position, but further studies in humans are warranted.

References

1. Braakenburg, A., Obdeijn, M. C., Feitz, R., et al. The clinical efficacy and cost effectiveness of the vacuum-assisted closure technique in the management of acute and chronic wounds: a randomized controlled trial. *Plast. Reconstr. Surg.* 118(2):390–397; discussion 398–400, 2006.
2. DeFranzo, A. J., Argenta, L. C., Marks, M. W., et al. The use of vacuum-assisted closure therapy for the treatment of lower-extremity wounds with exposed bone. *Plast. Reconstr. Surg.* 2001. 108(5):1184–1191.
3. Morykwas, M. J., Argenta, L. C., Shelton-Brown, E. I., et al. Vacuum-assisted closure: a new method for wound control and treatment: animal studies and basic foundation. *Ann. Plast. Surg.* 38(6):553–562, 1997.
4. Saxena, V., Hwang, C.-W., Huang, S., et al. Vacuum-assisted closure: microdeformations of wounds and cell proliferation. *Plast. Reconstr. Surg.* 114(5):1086–1096; discussion 1097–1098, 2004.
5. Greenwald, A. S., Haynes, D. W. A pathway for nutrients from the medullary cavity to the articular cartilage of the human femoral head. *J. Bone Joint Surg. Br.* 51(4):747–753, 1969.
6. Mitchell, N., Shepard, N. The deleterious effects of drying on articular cartilage. *J. Bone Joint Surg. Am.* 71(1):89–95, 1989.
7. Speer, K. P., Callaghan, J. J., Seaber, A. V., et al. The effects of exposure of articular cartilage to air. A histochemical and ultrastructural investigation. *J. Bone Joint Surg. Am.* 72(10):1442–1450, 1990.
8. Lee, D. A., Salih, V., Stockton, E. F., et al. Effect of normal synovial fluid on the metabolism of articular chondrocytes in vitro. *Clin. Orthop. Relat. Res.* 342:228–238, 1997.
9. Othman, T., Friese, G., Smentek, J., et al. [Granulation tissue induced by vacuum-therapy on the exposed chondral part of the condyle of femur after disarticulation of the knee]. *Zentralbl. Chir.* 131(suppl. 1):S151–S152, 2006.
10. Curtiss, P. H., Jr. Cartilage damage in septic arthritis. *Clin. Orthop. Relat. Res.* 64:87–90, 1969.
11. Smith, R. L., Schurman, D. J., Kajiyama, G., et al. The effect of antibiotics on the destruction of cartilage in experimental infectious arthritis. *J. Bone Joint Surg. Am.* 69(7):1063–1068, 1987.
12. BD Biosciences. *Analysis of Apoptotic Cells Using the BD FACSAry Bioanalyzer*, 2008.
13. Surendran, S., Kim, S. H., Jee, B. K., et al. Anti-apoptotic Bcl-2 gene transfection of human articular chondrocytes protects

- against nitric oxide-induced apoptosis. *J. Bone Joint Surg. Br.* 88(12):1660–1665, 2006.
14. Kothakota, S., Azuma, T., Reinhard, C., et al. Caspase-3-generated fragment of gelsolin: effector of morphological change in apoptosis. *Science* 278(5336):294–298, 1997.
 15. Ulrich-Vinther, M., Maloney, M. D., Schwarz, E. M., et al. Articular cartilage biology. *J. Am. Acad. Orthop. Surg.* 11(6):421–430, 2003.
 16. Mankin, H. J., Lippiello, L. The glycosaminoglycans of normal and arthritic cartilage. *J. Clin. Invest.* 50(8):1712–1719, 1971.
 17. Maroudas, A., Bullough, P., Swanson, S. A. V., et al. The permeability of articular cartilage. *J. Bone Joint Surg. Br.* 50(1):166–177, 1968.
 18. Collins, D. *The Pathology of Articular and Spinal Diseases*, Edward Arnold & Co., London, 1949.
 19. Ekholm, R. Nutrition of articular cartilage: a radioautographic study. *Acta Anat. (Basel)* 24(3–4):329–338, 1955.
 20. McKibbin, B., Holdsworth, F. W. The nutrition of immature joint cartilage in the lamb. *J. Bone Joint Surg. Br.* 48(4):793–803, 1966.
 21. Berry, J. L., Thaeler-Oberdoerster, D. A., Greenwald, A. S. Subchondral pathways to the superior surface of the human talus. *Foot Ankle* 7(1):2–9, 1986.
 22. Clark, J. M. The structure of vascular channels in the subchondral plate. *J. Anat.* 171:105–115, 1990.
 23. Holmdahl, D. E., Ingelmark, B. E. The contact between the articular cartilage and the medullary cavities of the bone. *Acta Orthop. Scand.* 20(2):156–165, 1950.
 24. Milz, S., Putz, R. Quantitative morphology of the subchondral plate of the tibial plateau. *J. Anat.* 185(Pt 1):103–110, 1994.
 25. Roberts, S., Menage, J., Urban, J. P. Biochemical and structural properties of the cartilage end-plate and its relation to the intervertebral disc. *Spine* 14(2):166–174, 1989.
 26. Nachemson, A., Lewin, T., Maroudas, A., et al. In vitro diffusion of dye through the end-plates and the annulus fibrosus of human lumbar inter-vertebral discs. *Acta Orthop. Scand.* 41(6):589–607, 1970.
 27. Nakano, T., Thompson, J. R., Christopherson, R. J., et al. Blood flow distribution in hind limb bones and joint cartilage from young growing pigs. *Can. J. Vet. Res.* 50(1):96–100, 1986.
 28. Imhof, H., Breitenseher, M., Kainberger, F., et al. Importance of subchondral bone to articular cartilage in health and disease. *Top. Magn. Reson. Imaging* 10(3):180–192, 1999.