

Allograft Reconstruction of Chronic Pectoralis Major Tendon Ruptures

Michael A. Zacchilli, MD¹; Justin T. Fowler, MD¹; and Brett D. Owens, MD^{1,2}

In chronic pectoralis tendon tears, primary repair may not be possible and allograft reconstruction may be required. The goal of this study was to report the authors' experience with chronic pectoralis major tendon reconstructions using an Achilles tendon allograft in three military patients. Three consecutive patients presenting with chronic, complete pectoralis major tendon tears underwent reconstruction by a single surgeon using the same described technique at a mean of 22.2 months after initial injury. Final outcomes were assessed at a mean of 24.5 months postoperatively, yielding one excellent and two good results. All patients were satisfied. All patients returned to full active duty military service and recreational weight lifting by 6 months. Achilles allograft reconstruction of chronic pectoralis major tendon ruptures is a viable treatment option. Good to excellent results can be achieved in active patients, even when reconstruction is performed nearly 2 years from the time of injury. (Journal of Surgical Orthopaedic Advances 22(1):95–102, 2013)

Key words: Achilles, allograft, chronic, pectoralis, reconstruction, rupture, tear

Pectoralis major tendon tears are relatively rare injuries, with approximately 180 cases described in the medical literature since the initial description in 1822 (1). Acute direct repair is an established treatment option, because numerous studies have shown that either nonoperative management or delayed surgical intervention leads to inferior outcomes (1–6). In challenging cases of chronic complete tears, muscle retraction and involution of residual tendon can preclude the use of direct repair as a surgical technique. To the best of our knowledge, only seven such cases have been previously reported in the English medical literature, representing less than 5% of all documented pectoralis ruptures. Recommended graft options included one case of tubularized Achilles allograft

reconstruction, two cases of bone–patellar tendon allograft reconstruction, one case of fascia lata allograft reconstruction, and three case of hamstring autograft (7–11). Fixation for these techniques included suture anchors, bone tunnels, or screw-and-washer techniques. One additional case report described the use of proximal fascial detachment in order to eliminate undue tension on a delayed primary repair (12).

The military population seems to be particularly susceptible to pectoralis major tendon ruptures, with 21 reported cases representing roughly 12% of all cases in the medical literature (13, 14). This disproportionate prevalence may be related to the high physical demands placed on the active duty military, as well as the popularity of weight training in this population. Similarly, frequent field training and deployments increase the risk for a delay in diagnosis and treatment. These trends were recently supported by the experience of the senior author, who in a 6-month period treated three patients for chronic pectoralis tendon ruptures, none of whom were candidates for primary repair at the time of surgical intervention. Each patient underwent a reconstruction with Achilles tendon allograft.

Materials and Methods

Following approval from the institutional review board, a retrospective review was performed for three active duty service members treated with Achilles allograft reconstruction of chronic pectoralis major tendon tears between July 2008 and January 2009. Preoperative and postoperative orthopedic and physical therapy records

From ¹Department of Orthopedics and Rehabilitation, William Beaumont Army Medical Center, El Paso, Texas; ²John A. Feagin, Jr. Sports Medicine Fellowship, Keller Army Community Hospital, West Point, New York. Address correspondence to: LTC Brett D. Owens, MD, Keller Army Community Hospital, West Point, NY 10996; e-mail: b.owens@us.army.mil.

All of the authors of this article are members of the United States military and/or employees of the U.S. Government. The opinions or assertions contained herein are the private views of the authors and are not to be construed as official or reflecting the views of the Department of the Army, Department of Defense, or the United States Government. One of the authors (BDO) is a consultant for MTF and MITEK.

This study was approved by the institutional review board at William Beaumont Army Medical Center and Madigan Army Medical Center.

Received for publication September 6, 2012; revision received November 11, 2012; accepted for publication November 20, 2012.

For information on prices and availability of reprints, e-mail reprints@datatrace.com or call 410–494–4994, x232.

1548-825X/13/2201-0095\$22.00/0
DOI: 10.3113/JSOA.2013.0095

pertaining to the injured extremity were obtained and reviewed. Operative reports, intraoperative photographs, and postoperative clinical photographs were also obtained.

Demographic characteristics were recorded for each patient, including age (at injury, surgery, and final follow-up), gender, rank, and military job. Surgical results were classified based on the system of Bak et al. (2) (Table 1). Primary objective measures of outcome included ability to continue active duty service without need of permanent profiles (a military proxy for limitation of physical demands), ability to remain in presurgical Military Occupational Specialty (MOS), and continuation of active duty service.

When available, subjective functional results were assessed retrospectively based on measures obtained in postoperative follow-up, including the Single Assessment Numeric Evaluation (SANE) score, the Disabilities of the Arm, Shoulder, and Hand (DASH) score, and an abbreviated subjective questionnaire based on the prior work of Antosh et al. in a military population (13, 15). The DASH scores were also used during follow-up in these cases because it is a commonly reported outcome measure in prior pectoralis repair studies and has been validated as an outcome measure in the military population (16). Similarly, the SANE score has been validated in the military

population and is a simple and expeditious measure of subjective function (16).

Surgical Technique

The patient was placed under general anesthesia and positioned in a reclined beach chair position with a pneumatic arthroscopic arm holder used to stabilize the operative extremity. General anesthesia allowed for utilization of muscle paralysis, which was critical when mobilizing the pectoralis muscle belly. The involved extremity was prepped and draped, with care to extend the operative field superiorly above the level of the clavicle and medially to the sternum.

The shoulder was examined with attention to the axillary fold with the arm in an abducted, forward elevated, and externally rotated position. The deltopectoral interval was identified and the normal position of the inferior margin of the axillary fold was estimated and marked. An incision 6 to 8 cm in length was planned along the interval centered over the desired position of the axillary skin fold and a standard deltopectoral interval was used. The cephalic vein was mobilized laterally with a cuff of fascial tissue to allow for ease of closure. Exposure was maintained with a skin rake medially and a wide, blunt retractor placed carefully beneath the deltoid insertion laterally, with care taken to avoid placing undue tension on this lateral retractor.

Inspection of the pectoralis musculotendon construct was performed and complete rupture of both the sternal and costal heads at the tendinous insertion was confirmed. Chronic isolated rupture of the sternal head has been described and preservation of the clavicular head may prevent severe retraction of the ruptured portion of the muscle, allowing primary repair years after injury (17). The end of the pectoralis major muscle was located (generally in a retracted, medialized position adherent to the chest wall). Examination of the tendinous end revealed substantial loss of tendon fibers, while the pectoralis muscle fascia more medially remained largely intact. Traction sutures were placed laterally into the superior and inferior borders of the pectoralis major muscle and fascia. Circumferential release of the lateral muscle belly and tendon was performed to facilitate mobilization, including digital and manual blunt dissection of subcutaneous and chest wall adhesions.

The humeral insertion of the pectoralis major was identified at its anatomic position, directly lateral to the bicipital groove. Because no residual tendon stump was present, the anatomic footprint of the pectoralis major tendon was localized according to the cadaveric work by Carey and Owens (18) with the superior aspect of the footprint located approximately 5 cm distal to where the greater tuberosity meets the bicipital groove.

TABLE 1 Pectoralis repair surgical outcome grading criteria

Excellent	
a.	Pain free.
b.	Full range of motion.
c.	Symmetrical manual adduction strength or <10% isokinetic strength deficit.
d.	Return to previous activity without restrictions.
e.	No cosmetic complaints.
Good	
a.	Slight pain not affecting return to activity.
b.	Slight restriction in motion.
c.	Slight restriction in function.
d.	Slight restriction in strength with symmetrical manual adduction strength or <20% isokinetic strength deficit.
e.	No cosmetic complaints.
Fair	
a.	Pain affecting return to activity.
b.	Restricted motion affecting return to activity.
c.	Weakness affecting return to activity.
d.	Assymetrical manual adduction strength or ≥20% isokinetic strength deficit.
e.	Unsatisfactory cosmetic result.
Poor	
a.	Treatment failure including: <ol style="list-style-type: none"> 1. Significant surgical complication. 2. Persistent pain. 3. Persistent restriction in motion. 4. Persistent weakness.

Adapted from Bak et al. (2).

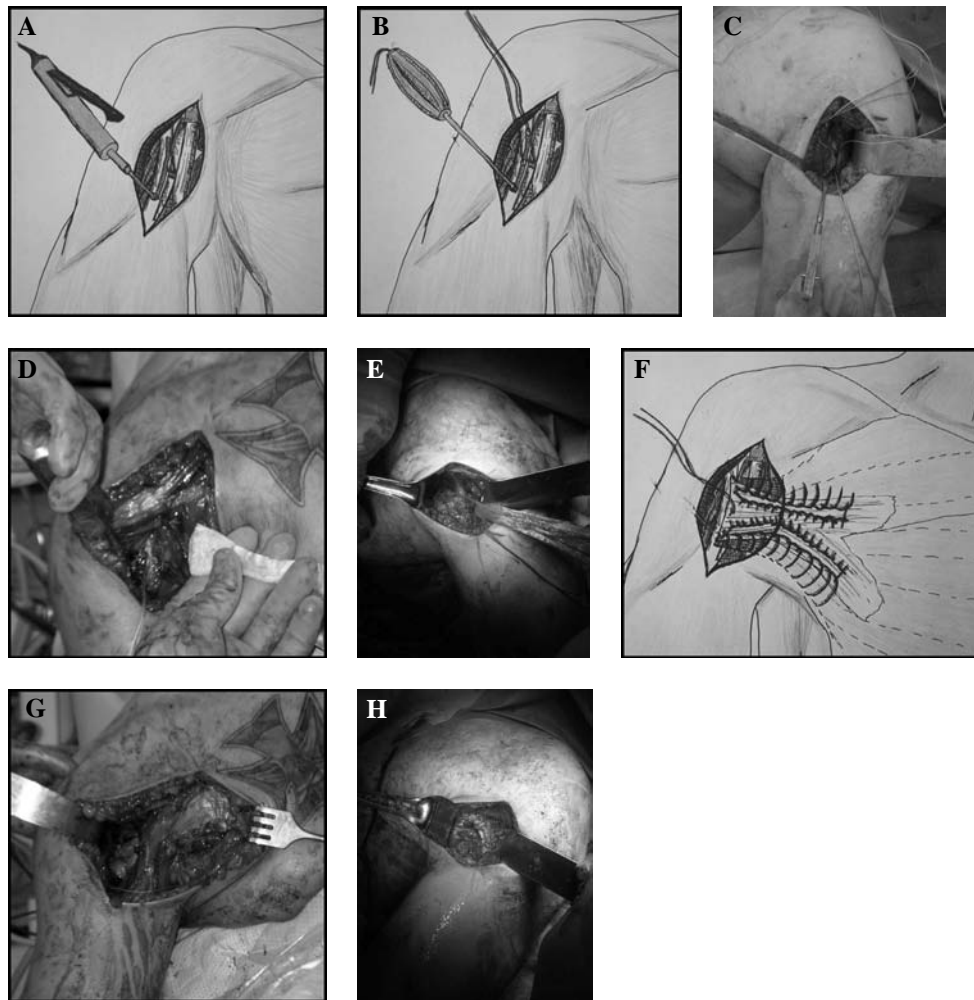


FIGURE 1 Operative technique. Deltopectoral approach is used to locate the pectoralis major tendon insertion and a trough is created with a burr (A). Double-loaded suture anchors are placed into the trough (B), as seen in patient 3 (C). The Achilles allograft has the bone block removed and the distal end is secured into the trough with the suture anchors, as seen in patient 2 (D). The tendon remnant is located and tag stitches are placed to facilitate mobilization, as seen in patient 3 (E). The proximal end of the graft is secured to the muscle belly and tendon remnant with No. 5 nonabsorbable suture, as seen in the artist's rendition (F), patient 3 (G), and patient 2 (H).

Preparation of the anatomic humeral insertion site was performed with resection of any remaining fibrous tissue and creation of a small trough using a narrow double-action rongeur or handheld burr (Fig. 1A). Three 3.5-mm suture anchors preloaded with No. 2 high tensile suture (Arthrex Corkscrew, Naples, FL) were inserted into predrilled holes in the trough (Fig. 1, B and C). The Achilles tendon allograft was prepared by removing the bone block, and the distal end of the Achilles allograft tendon was secured into the trough with the anchor sutures (without tension on the graft) (Fig. 1D). The arm was then adducted to the side and internally rotated. Lateral tension was placed on the traction sutures within the pectoralis muscle (Fig. 1E). The Achilles allograft was laid over the muscle and medially directed tension was maintained with Alice clamps. A No. 5 Ethibond suture with a large needle

was passed through the allograft and underlying pectoralis muscle and fascia using a Krackow technique (Fig. 1, F to H). Care was taken to secure muscle fibers from superior, middle, and inferior portions of the muscle to the allograft, because moment arm analysis of each of these subunits has suggested independent roles for each (19). Particular attention was paid to the most inferior segments of the sternal head for two reasons: first, these fibers have demonstrated the largest excursion during biomechanical testing; and second, their inclusion is important for recreation of the normal contour of the axillary fold (6). The fascia and skin were closed in a standard fashion.

Postoperatively, the patient was protected with the operative extremity in an adducted position in a sling for a total of 6 weeks with therapy limited to daily adducted pendulum exercises and wrist and elbow range of motion.

Forward elevation was limited to 90°, with guarding against external rotation and abduction. At 6 weeks, the patient progressed to full range of motion, with strengthening starting at 12 weeks. Patients were cleared for return to full duty and sports at 6 months.

Results

Three active duty service members (mean age, 28.7 years) sustained pectoralis major tendon ruptures with three different mechanisms (direct trauma, weight lifting, lifting a heavy object), all involving eccentric loading of the muscle. Accurate diagnosis of the injury occurred at a mean of 4.4 months after the initial injury. Patients reported having been counseled regarding the need for surgical intervention. All patients initially requested nonoperative treatment and physical therapy because of operational demands and a desire to continue current military missions. Patients presented to our facility with continued pain and disability and were offered surgical reconstruction. All patients noted their pectoralis muscle cramping when flexed and becoming prominent anteriorly (Fig. 2A).

Allograft reconstruction was performed an average of 22.2 months after initial injury. Findings at time of surgery revealed complete rupture of the sternal and clavicular heads of the pectoralis major with retraction and involution of the tendon preventing mobilization and primary repair despite circumferential releases. All patients underwent Achilles tendon allograft reconstruction by a single surgeon using the technique described above. Final surgical and functional outcomes were assessed at an average postoperative follow-up of 24.5 months. Surgical results are summarized in Table 2. No patient required separation from active military service. All patients returned to duty at a mean of 2.3 months, with one successfully completing a full combat deployment beginning just 6 months after surgical reconstruction. None required a change of MOS. Two of three patients reported very mild intermittent pain or “tightness” with strenuous activities even after full recovery, but denied any effect of this pain on activity level or function. One patient resumed normal push-ups at his preinjury level but maintained a physical profile exempting him from

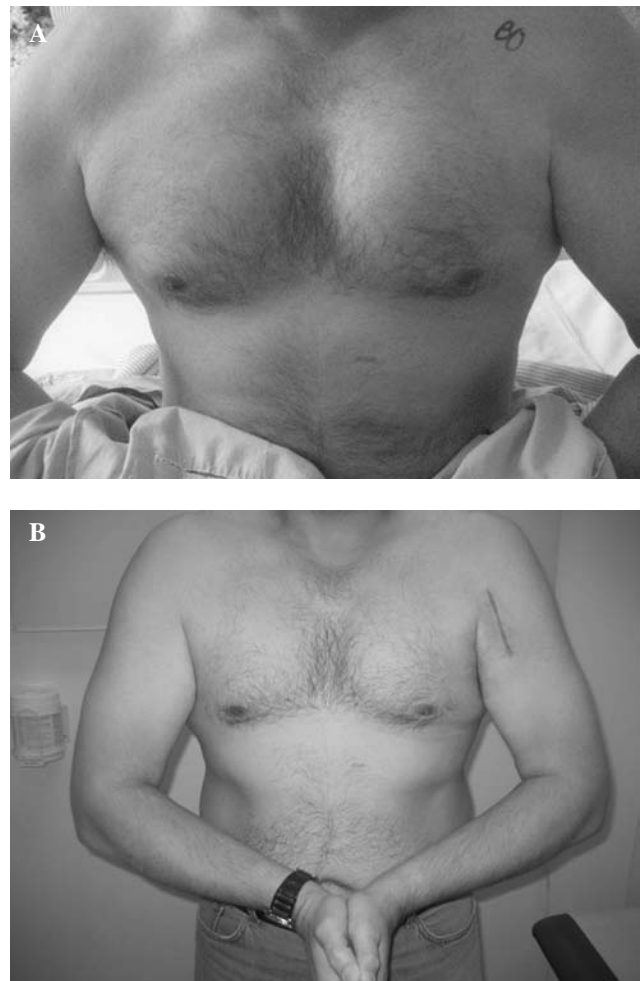


FIGURE 2 Clinical photographs of patient 3. Preoperatively, the patient noted cramping of his muscle belly when flexed and anterior prominence of the muscle (A). Postoperatively, the patient was happy with his outcome and noted return of normal strength, as well as cosmetic contour of his chest (B).

formal testing of push-ups as part of his Army Physical Fitness Test for administrative reasons. The third patient was able to return to full recreational weight lifting without any limitations and regained full preinjury strength, complaining only of the effect of the injury and subsequent reconstruction on his golf swing (Fig. 2B). One patient was very satisfied and the other two were

TABLE 2 Patient data

Patient	Age	Mechanism	Delay to Diagnosis (Months)	Delay to Surgery (Months)	Postop Follow-up (Months)	Surgical Result (Bak et al.)	SANE	DASH
1 MK	23	Trauma (static line)	3	37.7	23.5	Good	70	6
2 JM	23	Bench pressing (295 lb)	7.1	14.3	24	Good	78	6.7
3 GM	40	Heavy lifting	3	14.5	26	Excellent	90	10
Mean	28.7		4.4	22.2	24.5		79.3	7.6

satisfied with the surgical outcomes, with outcomes rated excellent ($n = 1$) and good ($n = 2$) based on the system of Bak et al. (2).

Discussion

Rupture of the pectoralis major muscle is a rare injury. Although early surgical repair is indicated, delay in either diagnosis or treatment may result in chronic tears. These chronic injuries may preclude the surgeon's ability to obtain tendon-to-bone contact at the time of surgery, necessitating allograft reconstruction. We report a small series of patients who underwent reconstruction with an Achilles tendon allograft with good to excellent outcomes.

Primary repair is well supported in the literature with excellent results. Park and Espiniella (4) reported results clearly favoring operative treatment as early as 1970 when, in their review of 29 cases, they reported 80% excellent and 10% good results in patients treated surgically as compared with 17% excellent and 58% good results in patients treated conservatively. Additionally, acute repair (usually defined as less than 3 to 6 weeks) appears to provide superior results relative to delayed intervention. In 2000, Schepesis et al. (5) described a series of patients with pectoralis major ruptures and compared a cohort of patients undergoing acute primary repair (six patients; mean delay to surgery, 9 days) with those undergoing delayed primary repair (seven patients; mean delay to surgery, 7 months). The authors were unable to demonstrate statistically significant differences between acute and delayed surgical repairs in subjective or objective measures, although trends favored acute repair. Specifically, acute repair demonstrated trends toward improved mean pain relief (95% vs. 89%), return of strength (94% vs. 90%), and overall satisfaction (96% vs. 93%). Isokinetic strength evaluation was performed on three patients from each surgical group at an average of 26.9 months after surgery. Expressed as a percentage of contralateral arm strength, acutely repaired patients demonstrated trends toward improved peak torque at three tested velocities (88.7% vs. 80%, 102.7% vs. 92.7%, and 100.3% vs. 95.7%), work/repetition (92% vs. 86.7%, 98% vs. 94.3%, and 102% vs. 95%), and fatigue index (102.7% vs. 101.7%, 104.7% vs. 97%, 102.7% vs. 94%) (5). In 2004, Äärilä et al. (1) attempted to elucidate differences in acute versus delayed (>3 weeks) repair in a larger series of their own patients (15 acute: mean, 2.1 weeks; 18 delayed: mean, 19.6 weeks) as well as in a meta-analysis of cases reported in the medical literature (32 acute, 19 delayed). When graded based on criteria similar to those of Bak et al., results in their own series demonstrated a nonsignificant trend toward improved results in the acute repair group (8 excellent, 7 good) as compared with the delayed repair group (5 good, 10 fair, 3 poor)

with a cumulative odds ratio of 3.7 (95% confidence interval, 0.9–15.1; $p = .07$). However, a meta-analysis of 73 historical cases demonstrated statistically superior outcomes with acute repair (18 excellent, 12 good vs. 8 excellent, 12 good) (1). In a second meta-analysis, Bak et al. (2) demonstrated a significantly higher percentage of excellent results in patients undergoing surgical repair at 0 to 8 weeks after injury relative to those undergoing intervention at 9 to 52 weeks after injury (57.8% vs. 16.7%). The findings of these meta-analyses have recently been strengthened by a 2009 study by Antosh et al. (13). Using a cutoff of 6 weeks in 14 active duty military service members, this study showed statistically superior functional measures for acute repair in both overall DASH and DASH Work Module scores (7.50 vs. 19.72 and 7.81 vs. 29.17, respectively). Also notable was a lower incidence of exertional pain in the acutely repaired group during routine activity (2/8 vs. 5/6) and strenuous activity (6/8 vs. 6/6) (13).

Acute primary repair therefore appears to be the best treatment option. Unfortunately, it may not always be a viable choice. As evidenced by prior reports and literature reviews, misdiagnosis and delay in presentation are not uncommon. Furthermore, as evidenced by two of the three cases in our series, patients may decline initial operative treatment even after an accurate diagnosis is obtained. Patients attempt to resume preinjury levels of activity as initial discomfort resolves and often find that functional limitations are greater than initially anticipated, prompting requests for delayed surgical intervention. Fortunately, in many of these cases (especially when the clavicular head is intact), findings at surgical intervention demonstrate that the rupture is amenable to delayed primary repair.

However, as evidenced by our series of patients, as well as in eight previously reported cases, substantial retraction of the muscle and involution of the pectoralis major tendon as early as 8 weeks after injury can make primary repair impossible. Various authors have therefore devised a number of surgical options, including fascial release or graft reconstruction. A summary of these techniques and their outcomes is presented in Table 3. While the small number of cases and large variability with regard to surgical technique, graft choice, and rehabilitation would render an in-depth statistical analysis unreliable, results to date indicate that our technique of Achilles allograft reconstruction of the pectoralis major offers results comparable with those previously described.

The Achilles allograft offers several theoretical advantages over previously published techniques. This graft is readily available at many institutions routinely performing orthopedic surgery such as primary or revision anterior cruciate ligament reconstructions. Although the use of

TABLE 3 Reported surgical procedures for chronic pectoralis major tendon tears

Study	Graft Type	Fixation	Tear Location	Delay to Surgery (Months)	Patients	Surgical Result Classification*	Satisfaction With Surgery	Function	Pain (ADL)	Pain (Strenuous Activity)
Current study	Achilles allograft	Suture anchors	Insertion	22.2	3	1 Excellent 2 Good	1 Very satisfied 2 Satisfied	1 Excellent 2 Good	3 None	1 None 2 Mild
de Castro Pochini et al., 2010 (7)	Hamstring autograft	Screw/washer	Insertion	>3	2	1 Excellent 1 Good	NR	1 Excellent 1 Good	NR	NR
Schachter et al., 2006 (9)	Hamstring autograft	Bone tunnels	Prior repair	3*	1	1 Excellent	1 Very satisfied	1 Excellent	None	None
Zafra et al., 2005 (11)	Bone - patella tendon autograft	Screw/washer	MT Junction	11	2	1 Good 1 Fair (cosmesis)	1 Satisfied 1 Unsatisfied (cosmesis)	2 Good	2 None	2 Mild
Sikka et al., 2005 (10)	Fascia lata allograft	Suture anchors	Insertion	60	1	Good or excellent* (pain not described)	Satisfied or very satisfied	Excellent or good	NR	NR
Joseph et al., 2003 (8)	Tubularized Achilles allograft	Suture anchors	Insertion	2	1	Good	Satisfied	Excellent or good	NR	NR
Alho, 1994 (12)	Pectoralis fascial release	Direct repair with bone tunnels	Insertion	3	1	Good or excellent* (pain not described)	NR	Excellent or good	NR	NR
Summary	—	—	8 Insertion 2 MT Junction 1 Prior repair	14.8	11	3 Excellent 2 Good/excellent 5 Good 1 Fair	2 Very satisfied 1 Satisfied/very satisfied 4 Satisfied 3 Unsatisfied	3 Excellent 3 Excellent / good 5 Good	6 None 5 NR	2 None 4 Mild 5 NR

ADL, activities of daily living; NR, not reported.

allograft introduces an extremely small risk of disease transmission, it obviates the need for complicated positioning or draping and eliminates donor site morbidity associated with autografts (7, 11, 12). The wide, thin distal end of the Achilles graft is ideal to mimic the pectoralis major tendon while the proximal end of the Achilles tendon fans out to allow for direct overlay onto the large retracted pectoralis muscle and muscle fascia, creating a large surface area for incorporation with an average length of 15 cm (20). There is a secondary benefit in this respect because it simplifies the procedure, making more complicated and time-consuming techniques such as tubularization (8), weaving (7, 10), and graft looping and cross-stitching (9) unnecessary.

The structural and biomechanical characteristics of the Achilles tendon also match well with those of the pectoralis major tendon. The pectoralis muscle consists of two heads: a uniform clavicular head and a sternocostal head consisting of two to seven segments (6, 21). The muscle then coalesces in a fashion described as either a laminated fan or a 90° twist into a bilaminar tendon with an inferior concave, fusing at its humeral insertion on the lateral edge of the intertubercular groove. Similarly, the Achilles tendon is commonly described as consisting of two main components undergoing approximately 90° of rotation before its insertion into the calcaneus (20). The insertional dimensions are roughly comparable, with the pectoralis insertion reported as 1.4 to 5 mm thick (medial to lateral) and 5 to 7.7 cm in length (proximal to distal) (6, 18, 21) and the Achilles insertion described as 6.9 mm thick and 2.0 to 4.8 cm in width (22). Taking an average of these measurements and assuming a roughly rectangular shape yields a calculated insertional footprint area for the pectoralis and Achilles tendons of 2.03 cm² and 2.35 cm², respectively.

Finally, the Achilles tendon is capable of withstanding impressive loads. In vivo measurements indicate that forces within the Achilles tendon can reach as much as 9 kN (approximately 12.5 times body weight) or 11,100 N/cm² during running or bounding activities (23). Biomechanical analysis of fresh-frozen Achilles allograft has demonstrated a mean ultimate tensile strength of 47.4 MPa (SD, 17.1) (24). Such properties are desirable in a graft for reconstruction of the pectoralis major, a muscle frequently used under high loads during demanding physical activities (i.e., heavy lifting or bench pressing).

It is important to recognize the limitations of this small, retrospective case series. Although our results were “good to excellent,” consistent with prior reports of reconstructions, we are unable to perform any meaningful statistical analyses. Although a large, randomized, controlled trial of specific reconstruction techniques with standardized measures of outcome would be necessary to definitively establish one technique as the gold standard, the extremely

rare occurrence of pectoralis ruptures would make such an undertaking exceedingly difficult. More important, there is an abundance of evidence showing that acute primary repair yields superior results. Ideally, this information should prompt acute intervention whenever possible and further decrease the incidence of delayed reconstructions requiring graft augmentation.

Conclusion

Chronic pectoralis major tendon tears may require allograft reconstruction if direct repair is not possible. Good to excellent results are possible with allograft reconstruction using an Achilles tendon graft fixed with suture anchors in an anatomic fashion.

References

1. Äärilä, V., Rantanen, J., Heikkilä, J., et al. Rupture of the pectoralis major muscle. *Am. J. Sports Med.* 32(5):1256–1262, 2004. doi:10.1177/0363546503261137
2. Bak, K., Cameron, E. A., Henderson, I. J. P. Rupture of the pectoralis major: a meta-analysis of 112 cases. *Knee Surg. Sports Traumatol. Arthrosc.* 8:113–119, 2000. doi:10.1007/s001670050197
3. Hanna, C. M., Glenny, A. B., Stanley, S. N., et al. Pectoralis major tears: comparison of surgical and conservative treatment. *Br. J. Sports Med.* 35(3):202, 2001. doi:10.1136/bjsm.35.3.202
4. Park, J. Y., Espiniella, J. L. Rupture of pectoralis major muscle: a case report and review of literature. *J. Bone Joint Surg. Am.* 52:577–581, 1970.
5. Schepesis, A. A., Grafe, M. W., Jones, H. P., et al. Rupture of the pectoralis major: outcome after repair of acute and chronic injuries. *Am. J. Sports Med.* 28(1):9–15, 2000.
6. Wolfe, S. W., Wickiewicz, T. L., Cavanaugh, J. T. Ruptures of the pectoralis major muscle: an anatomic and clinical analysis. *Am. J. Sports Med.* 20(5):587–593, 1992. doi:10.1177/036354659202000517
7. de Castro Pochini, A., Ejnisman, B., Andreoli, C. V., et al. Pectoralis major muscle ruptures in athletes: a prospective study. *Am. J. Sports Med.* 38:92, 2010. doi:10.1177/0363546509347995
8. Joseph, T. A., DeFranco, M. J., Weiker, G. G. Delayed repair of a pectoralis major tendon rupture with allograft: a case report. *J. Shoulder Elbow Surg.* 12(1):101–104, 2003. doi:10.1067/mse.2003.128200
9. Schachter, A. K., White, B. J., Namkoong, S., et al. Revision reconstruction of a pectoralis major tendon rupture using hamstring autograft: a case report. *Am. J. Sports Med.* 2006; 34(2):295–298, 2006. doi:10.1177/0363546505278697
10. Sikka, R. S., Neault, M., Guanche, C. A. Reconstruction of the pectoralis major tendon with fascia lata allograft. *Orthopedics* 28(10):1199–1201, 2005.
11. Zafra, M., Muñoz, F., Carpintero, P. Chronic rupture of the pectoralis major muscle: report of two cases. *Acta Orthop. Belg.* 71(1):107–110, 2005.
12. Alho, A. Ruptured pectoralis major tendon. A case report on delayed repair with muscle advancement. *Acta Orthop. Scand.* 65(6): 652–653, 1994. doi:10.3109/17453679408994625
13. Antosh, I. J., Grassbaugh, J. A., Parada, S. A., et al. Pectoralis major tendon repairs in the active-duty population. *Am. J. Orthop.* 38(1):26–30, 2009.

14. White, D. W., Wenke, J. C., Mosely, D. S., et al. Incidence of major tendon ruptures and anterior cruciate ligament tears in US Army soldiers. *Am. J. Sports Med.* 35(8):1308–1314, 2007. doi:10.1177/0363546507301256
15. Hudak, P. L., Amadio, P. C., Bombardier, C. Development of an upper extremity outcome measure: the DASH (disabilities of the arm, shoulder, and hand) [corrected]. *Am. J. Ind. Med.* 29(6): 602–608, 1996. doi:10.1002/(SICI)1097-0274(199606)29:6<602::AID-AJIM4>3.0.CO;2-L
16. Clarke, M. G., Dewing, C. B., Schroder, D. T., et al. Normal shoulder outcome score values in the young, active adult. *J. Shoulder Elbow Surg.* 18:424–428, 2009. doi:10.1016/j.jse.2008.10.009
17. Anbari, A., Kelly, J. D., Moyer, R. A. Delayed repair of a ruptured pectoralis major muscle: a case report. *Am. J. Sports Med.* 28(2): 254–256, 2000.
18. Carey, P., Owens, B. D. Insertional footprint anatomy of the pectoralis major tendon. *Orthopedics* 33(1):23, 2010. doi:10.3928/01477447-20091124-27.
19. Ackland, D. C., Ponnaren, P., Richardson, M., et al. Moment arms of the muscles crossing the anatomical shoulder. *J. Anat.* 213:383–390, 2008. doi: 10.1111/j.1469-7580.2008.00965.x
20. Schepesis, A. A., Jones, H., Haas, A. L. Achilles tendon disorders in athletes. *Am. J. Sports Med.* 30(2):287–305, 2002.
21. Fung, L., Wong, B., Ravichandiran, K., et al. Three-dimensional study of pectoralis major muscle and tendon architecture. *Clin. Anat.* 22(4):500–508, 2009. doi:10.1002/ca.20784
22. Koivunen–Niemelä, T., Parkkola, K. Anatomy of the Achilles tendon (tendo calcaneus) with respect to tendon thickness measurements. *Surg. Radiol. Anat.* 17(3):263–268, 1995. doi: 10.1007/BF01795061
23. Komi, P. V. Relevance of in vivo force measurements to human biomechanics. *J. Biomech.* 23(suppl. 1):23–34, 1990. doi:10.1016/0021-9290(90)90038-5
24. Penn, D., Willet, T. L., Glazebrook, M., et al. Is there significant variation in the material properties of four different allografts implanted for ACL reconstruction? *Knee Surg. Sports Traumatol. Arthrosc.* 17:260–265, 2009. doi: 10.1007/s00167-008-0678-8