Journal of
Surgical Orthopaedic Advances

LETTER TO THE EDITOR

Differential Diagnosis of Foot Drop: Foot Drop Stroke Syndrome

Dear Editor:
We read with great interest the article by Mitsiokapa et al. on foot drop 48 hours after an inversion ankle sprain (1). Besides delayed manifestation, peroneal palsy is not infrequently painless, so that the making of the diagnosis is often complicated (2). By reporting a case of painless foot drop, we wish to call attention to a central etiopathogenesis due to ischemic stroke.

A 53-year-old woman with a history of smoking (30 pack years) noticed during her job as a supermarket cashier a sudden problem in elevation of her right foot. She was no longer able to continue her work because she was unable to handle the foot pedal that operated the conveyor belt. She did not report on numbness, pain, or any dysfunction of face, arm, visual capacity, and speech. The clinical examination revealed a reduced strength of the right dorsiflexion, graded 3/5, the right great toe extension (3/5), and slight plantarflexion (4–5/5). The strength in the other muscle groups was normal. The knee and ankle reflexes and sensation were normal as well. The muscle tone was normal and the Babinski test was negative. The patient's magnetic resonance imaging showed a circumscribed focal high-intensity signal in the left precentral region at the high convexity compatible with acute ischemic stroke (Fig. 1A). In addition a complete occlusion of the internal carotid artery was found where the circle of Willis on the left side was visible.

Foot drop is an index symptom and needs a careful differential diagnosis (3). Radiculopathy and peroneal palsy, as in the patient described by Mitsiokapa et al. (1), are the most frequent causes, but rarely lesions of the central motor cortex and its corresponding fiber system have to be considered. So far, Narenthiran et al. have collected just 18 cases with central foot drop in the English language literature, most of them are due to meningioma (4). Reports on monoparesis resulting from ischemic stroke describe only some singular cases with isolated foot drop mimicking peripheral palsy (5–7). This syndrome was only observed if the lesion affected the rear portion of the medial precentral gyrus (5). In our patient, the topography of the lesion is nearly identical to the lesions described by Ku et al. (6) and Alonso et al. (7) affecting the precentral gyrus in the high convexity. This exact parasagittal region has recently been confirmed to represent ankle and toe movements as described in the pioneering work by Penfield and Rasmussen (Fig. 1B) (8).

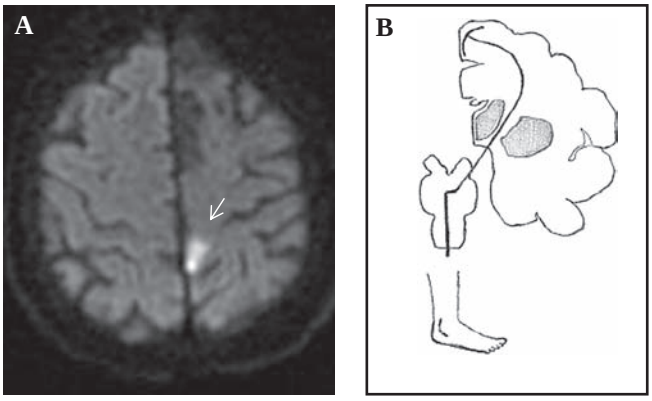

FIGURE 1 (**A**) Diffusion-weighted magnetic resonance imaging shows a hyperintensive signal at the rear portion of precentral gyrus at the high convexity (*arrow*). (**B**) Schematic drawing of the main motor cortex in a coronal view with the associated motor fiber system.

This reported case highlights two remarkable features. First, the index symptom foot drop can be caused by a circumscribed ischemic stroke in the corresponding motor area of the cortex and its fiber system. We propose the term "foot drop stroke syndrome" to memorize this condition easier in day-to-day clinical practice and recommend considering such a condition in the workup of foot drop. Second, a patent circle of Willis may compensate relatively well an occlusion of the internal carotid artery. This topic is addressed in detail elsewhere (9).

References

1. Mitsiokapa, E. A., Mavrogenis, A. F., Antonopoulos, D., et al. Common peroneal nerve palsy after grade I inversion ankle sprain. J. Surg. Orthop. Adv. 21:261–265, 2012.
2. Kyavar, L., Heckmann, J. G. Bilateral peroneal palsy after weightlifting. Clin. J. Sport Med. 23(5):400–402, 2013.
3. Stewart, J. D. Foot drop: where, why and what to do? Pract. Neurol. 8:158–169, 2008.
4. Narenthiran, G., Leach, P., Holland, J. P. Clinical features of central isolated unilateral foot drop: a case report and review of the literature. Surg. Neurol. Int. 2:27, 2011.
5. Hiraga, A. Pure motor monoparesis due to ischemic stroke. Neurologist 17:301–308, 2011.
6. Ku, B. D., Lee, E. J., Kim, H. Cerebral infarction producing sudden isolated foot drop. J. Clin. Neurol. 3:67–69, 2007.

7. Alonso, A., Gass, A., Griebe, M., et al. Isolated ischaemic lesions in the foot motor area mimic peripheral lower-limb palsy. J. Neurol. Neurosurg. Psychiatry 81:822–823, 2010.
8. Penfield, W., Rasmussen, T. *The Cerebral Cortex of Man: A Clinical Study of Localization of Function*. Macmillan, New York, 1950.
9. Khan, S. N. H. Complete internal carotid artery occlusion presenting as "seizures." J. Neurol. Res. 2:244–246, 2012.

Ivana Vachalova
Josef G. Heckmann, MME
Department of Neurology
Municipal Hospital Landshut
Landshut, Germany
e-mail: josef.heckmann@klinikum-landshut.de